



PATIENT

Chloe Dewey

SPECIES

Canine

BREED

Boston Terrier

SEX

Female Spayed

AGE

6 years

WEIGHT

25.6lbs

INTERPRETED BY

Maggie Machen Lamy,
DVM, DACVIM
(Cardiology)

IMAGING PERFORMED BY

Alastair Westcott,
DVM

HOSPITAL NAME

Dr. Alastair Westcott

REFERRING VET

Dr. Westcott

INVOICE

26604

DATE

9/28/22

PRESENTING CLINICAL SIGNS

History: Recheck echo. No clinical signs. Grade 3/6 heart murmur.

-Pertinent previous echo findings (2/2022 MML): Mild MR, minimal LAE, no LVE, trace TR: 2.7m/s. LA: 2.1, LV: 2.7.

ECHOCARDIOGRAM FINDINGS

2D, m-mode, color flow and doppler imaging is available. Mild diffuse thickening of mitral valve leaflets with mild prolapse into the left atrial lumen. Mild eccentric mitral regurgitation with minimal left atrial dilation. Normal MR velocity. Normal LV diameter with adequate myocardial function. The tricuspid valve appears normal with mild tricuspid regurgitation. Velocity consistent with early pulmonary hypertension. Normal right heart dimensions. The pulmonic and aortic valves are normal in morphology and mobility. Normal pulmonic and aortic outflow velocities with laminar flow. No obvious aortic or pulmonic insufficiency. No pericardial or pleural effusion noted. No obvious cardiac masses.

CARDIAC CHART

CANINE CARDIAC PARAMETERS	MR VMAX (m/s)	TR VMAX (m/s)	LA/AO (Boon method)	LA/AO (Heart Base; Swe)	FS (%)	EF (%)	EPSS (cm)
NORMAL PARAMETER	4.5-5.5	<2.7	1.3	<1.6	28-40	40-100	<0.6
PATIENT	4.8	3.3	NM	1.5	56	88	0.4
CANINE CARDIAC PARAMETERS	HR (BPM)	AV VMAX (m/s)	PV MAX (m/s)	BODY WEIGHT (kg)	LA 2D short axis Base view (cm)	LVIDd Avg; 2D and m-mode short axis (cm)	LVIDs Avg; 2D and m-mode short axis (cm)
NORMAL PARAMETER	50-100	0.7-1.7	0.7-1.6	BELOW	BELOW	BELOW	BELOW
PATIENT	NM	1.4	1.0	11.6	2.2	2.9	1.3
*Normal chamber parameters expressed as a mean value (SD)							
BODY WEIGHT DEPENDENT PARAMETERS							
<i>*Note: All measurements based upon multi-modal images and methods. An average value is reported.</i>							
Adapted from June Boon, Veterinary Echocardiography, 1998							
Rishniw M and Hollis NE, J Vet Intern Med 2000; 14:429-435							
Hansson et al, Vet Rad and Ultrasound 2002							
Bonagura et al. Echocardiography: principles of interpretation, Vet Clin North Am 15:1177, 1995							
				3	1.27 (5.3)	2.46 (2.46)	1.36 (5.5)
				5	1.40 (4.5)	2.74 (5.2)	1.60 (4.7)
				10	1.50 (3.8)	3.27 (3.5)	2.06 (3.1)
				15	1.83 (2.0)	3.71 (2.4)	2.43 (2.1)
				20	2.02 (1.9)	4.14 (2.2)	2.80 (2.0)
				25	2.18 (2.4)	4.48 (2.9)	3.10 (2.5)
				30	2.33 (3.3)	4.83 (3.9)	3.39 (3.4)
				35	2.48 (4.3)	5.17 (5.0)	3.69 (4.5)
				40	2.62 (5.2)	5.48 (6.1)	3.96 (5.4)
				50	2.88 (7.1)	6.07 (8.3)	4.46 (7.4)

INTERPRETATION OF THE FINDINGS & FURTHER RECOMMENDATIONS

Chronic degenerative valve disease persists with evidence of stability. Mild mitral and tricuspid regurgitation are similar to previous with a slight increase in TR quantity. Mild pulmonary hypertension has developed, which is of unknown significance in an asymptomatic dog. No treatment is warranted. No additional issues are identified.

Given these findings, no cardiac medications are indicated. Continued assessment of progression in the future will help predict long term prognosis, which is highly variable at this stage (B1).

Omega fatty acid supplementation and mild salt restriction may be of some long-term benefit.



PATIENT

Chloe Dewey

Monitor for development of a cough, labored breathing, exercise intolerance or collapse episodes.

SPECIES

Canine

Anesthetic risk is considered mild if needed. Cardiac protective drug choices (opioid/benzodiazepine premedication, propofol or alfaxalone induction, isoflurane gas) are recommended. Pre-oxygenate for 5-10 minutes prior to induction. Monitor for arrhythmias, hypotension, and hypoxia both intra and post-operatively and intervene as necessary. Mild IV fluid restriction is recommended to avoid fluid overload. Avoid heart rate stimulating drugs such as atropine unless clinically indicated.

BREED

Boston Terrier

Recommend conservative monitoring with a recheck echocardiogram in 6-12 months, sooner if any development of clinical signs.

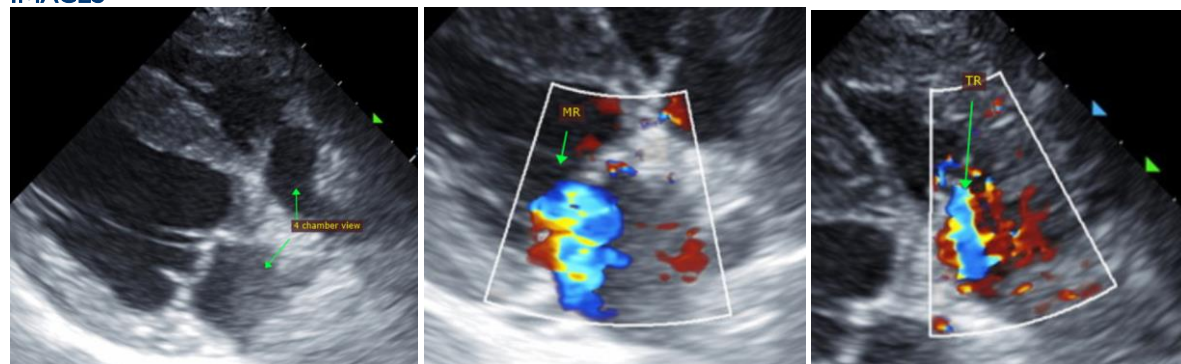
SEX

Female Spayed

AGE

6 years

IMAGES



WEIGHT

25.6lbs

INTERPRETED BY

Maggie Machen Lamy,
DVM, DACVIM
(Cardiology)

The information and recommendations provided are based on the images presented by the referring veterinarian. No evaluation can be communicated regarding pathology that was not visible in the image/video clips provided.

IMAGING PERFORMED BY

Alastair Westcott,
DVM

Thank you for this referral. This report was generated using transcription software, and minor dictation errors may be present. If the clinical or image interpretation does not parallel your findings or if I can be of any further assistance, please contact me.

HOSPITAL NAME

Dr. Alastair Westcott

Maggie Machen Lamy, DVM
Diplomate of the American College of Veterinary Internal Medicine (Cardiology)
info@sonopath.com

REFERRING VET

Dr. Westcott

INVOICE

26604

DATE

9/28/22